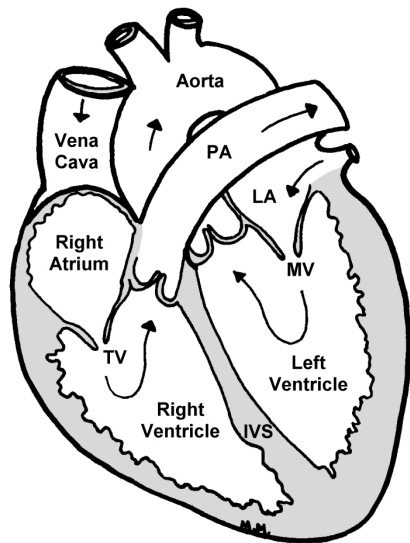


# Feline Hypertrophic Cardiomyopathy

Hypertrophic cardiomyopathy (HCM) is the most common heart disease in cats. It develops and progresses insidiously over time and its early signs may be subtle or nonexistent. A cat that seems healthy may appear to become very ill very quickly, or even die suddenly.



© Copyright 1999 M. J. Munro. All rights reserved.

**The feline heart.** *IVS = Interventricular Septum;*  
*LA = Left Atrium;*  
*MV = Mitral Valve;*  
*PA = Pulmonary Artery;*  
*TV = Tricuspid Valve.*

Hypertrophic cardiomyopathy is a heart muscle disease in which the muscular walls of the left ventricle become abnormally thickened. Internal cardiac structures, such as the papillary muscles, also thicken. HCM is diagnosed when it is determined that the muscle thickening is not caused by another illness such as hyperthyroidism, systemic hypertension, or any of several other more rare diseases.

HCM is seen in cats at almost any age. Familial occurrences have been observed in several breeds, and in these instances cats are most commonly diagnosed when they are less than five years of age. While specific feline genetic mutations have not been isolated as yet, the pattern of inheritance in families of cats strongly indicates an autosomal dominant mode of inheritance, as is the case with humans.

To date, no viral or dietary causes of HCM have been identified in humans or animals.

As HCM develops and progresses, it alters the structure of the heart and impairs its function in several ways. While the hallmark of feline HCM is thickened left ventricular walls, early HCM is usually also characterized by enlarged papillary muscles and an effect called systolic anterior motion (SAM) of the mitral valve. This abnormal motion of the mitral valve may partially obstruct the outflow of blood from the left ventricle to the aorta. The abnormal mitral valve position also allows blood to flow backward, or regurgitate, into the left atrium. This distortion in the mitral valve's position causes a systolic heart murmur that often becomes louder with excitement or softens as a cat relaxes.

With HCM, the thickened left ventricular walls become stiff, which prevents the ventricle from relaxing sufficiently to fill with blood at a normal pressure from the left atrium. The increased pressure in the relaxed left ventricle increases pressure in the left atrium, which, in turn, enlarges. This increased pressure also backs up into the capillaries of the lung and the lining of the chest cavity and forces fluid from these capillaries into the lung tissue, causing pulmonary edema, and into the chest cavity, causing pleural effusion. These abnormalities are called congestive heart failure. They make it difficult for the cat to breathe.

Blood flow in the enlarged left atrium slows, which can cause blood clots to form in this heart chamber. A blood clot can dislodge and be forced by blood flow into the body's circulatory system, where it eventually becomes lodged and blocks the flow of blood to tissue beyond that point. A classic example of this is rear leg paralysis, which is caused when a clot lodges in the descending aorta at the point where it branches to go to each of the back legs. This situation is commonly referred to as a saddle thromboembolus.

Outward signs of HCM may include a barely noticeable increase in breathing rate to marked signs of respiratory difficulty, rear leg paralysis, or the sudden death of a cat that seemed healthy only moments earlier. Early signs can be so slight that even an observant owner may not notice them. Many cats with HCM develop a heart murmur, a gallop rhythm, and/or a rapid heart rate, which the cat's veterinarian may detect during a routine examination. An echocardiogram (an ultrasound of the heart) with color flow Doppler imaging is the most conclusive means of diagnosing HCM. While electrocardiograms (ECGs or EKGs) and X-rays may provide the veterinarian with additional useful information, they cannot be used to arrive at an unequivocal diagnosis. HCM may also be diagnosed at necropsy (veterinary autopsy); the clinician must consider several factors such as the thickness of the left ventricular walls, the weight of the heart, and the size of the left atrium. The heart often contracts after death, causing it to thicken. Consequently, an increase in thickness alone cannot be used to diagnose HCM. A normal cat heart should weigh less than 20 grams.

At present there is, unfortunately, no cure for HCM. The veterinarian may, however, prescribe one or more medications in an effort to reduce the signs of heart failure and to help the heart function as efficiently as possible. Treatment options and the specific drugs prescribed will vary depending on the cat's clinical signs and the heart's functional impairments. Calcium channel blockers and beta blockers are drugs that are commonly used in cats with HCM, either when they are in heart failure or before heart failure occurs. Beta blockers are particularly effective at reducing SAM. Cats in heart failure need a diuretic and an angiotensin converting enzyme (ACE) inhibitor. Fluid withdrawal from the chest is required if fluid is present in the chest cavity. Aspirin or other agents may be given in an attempt to prevent clot formation. A cat that is suffering from respiratory distress, acute heart failure, or limb paralysis requires veterinary care as quickly as possible. There is nothing you can do at home to relieve your cat's distress or pain.

If you have questions about your cat's treatment, please discuss them with your veterinarian. Never attempt to medicate your cat without veterinary instruction and supervision!

It is difficult to predict the course of HCM; the disease may progress rapidly or it may stabilize for a long period of time. The good news is that a cat with mild to moderate HCM may enjoy an essentially normal life for a number of years. The bad news is that the long-term outlook for a cat that is suffering from severe heart failure or a saddle thromboembolus is often guarded to poor despite everyone's best efforts.

For more information, please visit the Feline HCM site at <http://members.aol.com/jchinitz/hcm/>

Copyright © 1999 Jody A. Chinitz; Marcia J. Munro; and Mark D. Kittleson, DVM, Ph.D. All rights reserved.

This information sheet is not intended to be a diagnostic or prognostic tool, or to provide medical or treatment advice.

If your pet is ill, please have it examined by your veterinarian.

Individuals, veterinarians, and not-for-profit organizations may freely distribute paper prints of this information sheet provided they do so at no cost to the recipients. It must be printed in its entirety, including this notice, and no alterations are permitted. This information sheet may not be republished in any other form, print or electronic, nor may its file be distributed or copied to other locations on the Internet or in any network or other media, without the permission of the authors.